

MR Imaging in the Evaluation of Dementia of the Alzheimer Type

Gary K. Stimac^{1,2}, Patricia Prinz³, Burton Reifler^{3,4}
Rebecca Gerlach², Monique Genton¹

1. First Hill Diagnostic Imaging Center 1001 Boylston Avenue, Seattle, WA 98104
2. Department of Radiology, University of Washington School of Medicine, Seattle, WA
3. Department of Psychiatry and Behavioral Sciences, University of Washington
4. Present address, Department of Psychiatry and Behavioral Medicine, Bowman Gray School of Medicine, Winston-Salem N.C.

Presented at the Ninth Meeting of the International Society of Magnetic Resonance, Rio de Janeiro, Brazil June 29-July 5, 1986. Supported by grants from the Alzheimer Research Program and Biomedical Research Support Program, University of Washington; and by a grant from Berlex Laboratories Inc.

Address reprint requests to Dr. Stimac at First Hill Diagnostic Imaging Center

Introduction

Dementia affects 15% of men and women over age 65 (1). In the United States a total of 5 million men and women have this mental deterioration. The causes of dementia include atherosclerosis, neurodegenerative disorders, infection, metabolic abnormalities, hydrocephalus, and, the most common cause, Alzheimer's disease. It is estimated that 50 to 60% of all cases of senile dementia are of the Alzheimer type (DAT), and 10 to 20% are multiple infarct dementia (MID). Some patients have both DAT and MID (1).

The diagnosis of DAT can be suspected on clinical grounds but is only conclusively made at post mortem examination by the identification of neurofibrillary tangles and neuritic plaques. CT scanning has demonstrated cerebral atrophy in Alzheimer's disease

but this does not reliably separate DAT patients from normal elderly individuals (2-4).

MR has been applied on a limited basis to the evaluation of DAT, also with limited success (5,6). Although large ventricles and sulci can be identified, these findings are not specific for Alzheimer's disease. Measurement of T1 and proton density values on MR scans has also not reliably identified lesions of DAT. Furthermore, no parenchymal lesions specific to Alzheimer's disease have been seen on scans. Despite evidence that blood brain barrier (BBB) breakdown occurs in Alzheimer's disease (7) there have not been, to our knowledge, any reports of attempts to image BBB breakdown using MR in Alzheimer's disease.

The purposes of our investigation were to use MR to identify atrophic or structural abnormalities and determine whether contrast enhancement, either focal or diffuse, occurs in the brain of DAT patients.

Subjects and Methods

We evaluated MR scans in fifteen patients with DAT and seven control patients scanned for other disease. Twelve of the DAT patients were from the Alzheimer's Disease Clinical Research Center (ADCRC) roster; the remaining three had clinical signs and symptoms highly suggestive of DAT. The patients in the ADCRC roster were evaluated for mental function, global deterioration, functional capacity, and depression. The average age of the DAT patients was 70.0, and that of the controls 69.6. The DAT group had 8 men and 7 women; the control group had 5 men and 2 women.

Patients were scanned in 1cm axial slices using a 0.15 T resistive MR system (Picker International). T1- (TR600,TE40) and T2- (TR2000,TE60) weighted spin echo images were obtained. One ADCRC roster patient and two non-ADCRC roster patients

were scanned for the evaluation of concomitant disease (two had cerebral infarct, one had metastatic breast carcinoma) using Gd-DTPA dimeglumine as a paramagnetic contrast agent (Berlex Laboratories Inc, Cedar Knolls, N.J.) in a study of brain lesions for FDA approval of this agent. The two non-ADCRC patients had symptomatology highly suggestive of Alzheimer's disease but their diagnoses could not be further confirmed.

Scans were evaluated qualitatively for atrophy, structural abnormalities, parenchymal areas of abnormal intensity and, in the two patients noted above, enhancement. For the ADCRC patients and the controls, area measurements of the brainstem were obtained and compared with the area of the perimesencephalic CSF space plus brainstem. The measurements were made using computer-drawn boundaries at the inferior level of the mesencephalon. Where the brainstem cisterns were partially imaged on two adjacent slices, the average areas were used. A second set of area measurements was also made comparing the overall brain and CSF spaces at the same level.

The scans of the three patients scanned using GD-DTPA were evaluated subjectively for the presence of enhancing lesions. In the ADCRC patient, region-of-interest intensity measurements of the hippocampi, brainstem, lateral temporal cortex, and a Gd-DTPA standard were compared before and after contrast administration. The standard was attached to the patient's head during scanning. All measurements for a given scan were made from the same slice.

Results

A subjective appearance of prominent or enlarged sulci and ventricles was seen in all but one of the DAT patients. Similar findings were seen on four of the seven control patients. The general appearance of cerebral atrophy did not separate DAT from the nondemented patients. Furthermore, the ratio of brain area to brain plus CSF area at the level of the lateral ventricles was identical in the two groups (the ratio was 0.850).

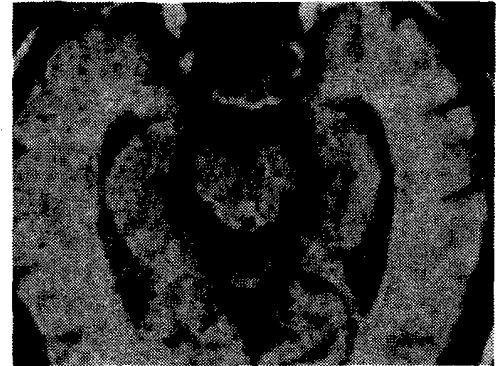

Figure 1. T1-weighted SE scan (TR 600, TE 40) in a patient with Alzheimer's disease shows large perimesencephalic cisterns and temporal horns, indicating medial temporal lobe atrophy.

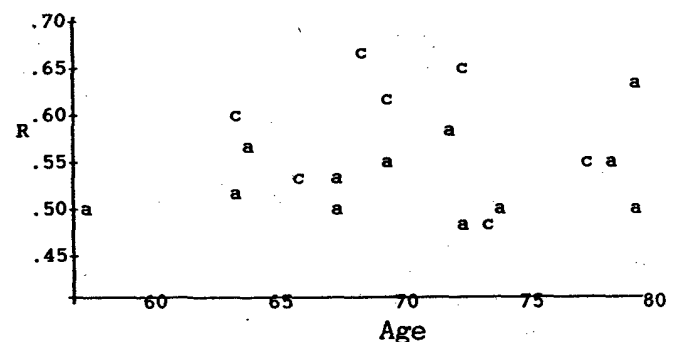


Figure 2. Ratio (R) of the area of the brainstem to perimesencephalic cistern plus brainstem as a function of age for patients with Alzheimer's disease (a) and controls (c).

The CSF spaces around the brainstem were best demonstrated on the T1-weighted images because of the high contrast between brain and CSF. Because the CSF was low intensity as compared with the surrounding brain and brainstem, the measurements were more easily made and are expected to be more accurate than CT measurements. Subjectively the CSF spaces around the brainstem appeared larger in the DAT patients (Figure 1) than in the controls, but there was overlap between the two groups. The ratio (R) of the brainstem to cistern plus brainstem, plotted as a function of age (Figure 2), shows a general trend toward smaller values for the DAT patients than the

controls. The average value of this ratio was 0.53 for the DAT patients and 0.58 for the controls. This difference of 9% was of similar magnitude to the variation in repeated individual measurements (6%).

A variety of structural abnormalities were detected on the noncontrast MR scans. These abnormalities included periventricular white matter disease, infarct, ventricular asymmetry, and cavum septum pellucidum. None of these lesions was considered related to DAT.

None of the three patients studied with Gd-DTPA showed enhancement. In one patient, a watershed area infarct showed no enhancement suggesting that the lesion was old. In the patient with metastatic breast carcinoma, multiple lesions in the deep white matter and the grey-white junction were evident on the noncontrast scan. Although these lesions were compatible with diffuse white matter disease (infarction or necrosis), two of the lesions would have been considered suspicious for metastases. Lack of enhancement of these lesions argued strongly against a diagnosis of metastases.

In the ADCRC patient studied with Gd-DTPA, the small lesion in the left temporal lobe did not enhance, ruling against a diagnosis of tumor or infection and making most likely a diagnosis of small old infarct. Intensity measurements in the brainstem, hippocampus and temporal cortex showed a small (3%) increase as compared with the standard following intravenous GD-DTPA. All three structures showed the same degree of enhancement.

Discussion

Many abnormalities were identified in our series of patients with Alzheimer's disease. These are best categorized as atrophic and structural abnormalities. Cerebral atrophy is well recognized in DAT but has not been useful in separating these patients from normals. The finding in one patient of focal temporal lobe atrophy is not typical of post mortem findings of the Alzheimer brain. The finding of slightly enlarged basilar cisterns may represent bilateral, diffuse medial temporal atrophy, a process that could explain the memory loss in these patients. This finding was recently noted

in the CT literature (8), but there has not been, to our knowledge, a report of measurements of these spaces, presumably because they cannot be well defined by CT. Measurements of the hippocampus using coronal inversion recovery MR have recently been presented (9) and also indicate atrophy of the hippocampus.

The finding of a cavum septum pellucidum in one patient might indicate a normal variant, but this has been reported in DAT, possibly related to trauma (10). The patchy areas of deep white matter and periventricular high signal intensity were seen on fourteen of the 15 patients. Such lesions are often seen in elderly patients many of whom are neurologically and mentally normal (11-13). Although these lesions are compatible with infarction, necrosis, or demyelinating disease, they also appear to represent a normal aging process (10-13). The patients who exhibited these lesions did not have clinical MID.

Gd-DTPA has been effective in demonstrating areas of BBB breakdown in human investigations (14) and may soon be available for routine use. In the brain it has been effective in enhancing tumors and inflammatory disease. White matter infarcts do not enhance (15) and demyelination has shown enhancement only in the acute stages (16). The three patients scanned with Gd-DTPA showed no evidence of enhancement. The lack of confirmation of DAT in two of these patients and the small sample size prevent any conclusions regarding enhancement in this disease. It seems probable that enhancement, if it occurs, will be diffuse, like the brain involvement. Region-of-interest intensity measurements in a larger series of patients may demonstrate enhancement in areas of the brain commonly affected in DAT.

Conclusion

MR is capable of better anatomical delineation than CT and demonstrates atrophic changes in Alzheimer's disease. Enlargement of the basal cisterns appears to represent atrophy in the medial temporal lobes. In our limited study, this atrophy was slightly more severe in patients with DAT, but, as with other measurements of atrophy on CT, does not

reliably differentiate DAT from other conditions.

Multiple structural abnormalities were detected but none appear to represent abnormalities of Alzheimer's disease. Deep white matter areas of high signal intensity were seen in the majority of patients and controls. If these represent infarction, present clinical techniques are insufficiently accurate to differentiate DAT from MID and from diffuse white matter changes of aging. No enhancement suggestive of BBB breakdown was detected in the three DAT patients studied using Gd-DTPA, but no conclusions can be drawn from our limited experience.

References

1. Katzman R. Alzheimer's disease. *NEJM* 1984, 314:964-973
2. McGeer PL. Brain imaging in Alzheimer's disease. *Brit Med Bull* 1986, 42:24-28
3. Fox JH, Kasniak AW, Huckman MS. Computerized tomographic scanning not very helpful in dementia. *New Engl J Med* 1979, 300: 437
4. George AE, deLeon MJ, Gentes CI, et al. Leukoencephalopathy in normal and pathologic aging: 1. CT of brain lucencies. *AJNR* 1986, 7:561-566
5. Besson JAO, Corrigan FM, Foreman EI et al. Differentiating senile dementia of Alzheimer type and MID by proton NMRI. *Lancet* 1983, 2:789
6. George AE, de Leon MJ, Kalnin A, et al. Leukoencephalopathy in normal and pathologic aging: 2. MRI of Brain Lucencies. *AJNR* 1986, 7:567-570
7. Wisniewski HM, Kozlowski PB. Evidence for blood-brain barrier changes in senile dementia of the Alzheimer type (SDAT). *Annals of the New York Acad of Sci* 1982, pp 119-129.
8. LeMay M. CT changes in dementing diseases: a review. *AJNR* 1986, 7:841-853
9. Seab JP, Wong S, Roos MS, Jagust WJ. NMR neuroimaging in Alzheimer's disease. *Proceedings of the Society of Magnetic Resonance in Medicine*, August 1987, Vol 2, p 46
10. Ruddli R, Strom JO, Welch PT, Ambler MW. Posttraumatic, premature Alzheimer's disease. *Arch Neurol*, 39:570-575, 1982.
11. Zimmerman RD, Fleming CA, Lee BCP, Saint-Louis LA, Deck MDF. Periventricular hyperintensity as seen by magnetic resonance: prevalence and significance. *AJNR* 1986, 7:13-20
12. Brant-Zawadzki M, Fein G, Van Dyke C, et al. MR imaging of the aging brain: patchy white-matter lesions and dementia. *AJNR* 6:675-682, 1985
13. Stimac GK, Grafton S, Sumi SM. Unpublished data in post mortem brain studies of demented and normal elderly patients.
14. Felix R, Schorner W, Laniado M, et al. Brain Tumors: MR imaging with Gd-DTPA. *Radiology* 1985;156:681-688
15. Mancuso A, Virapongse C, Quisling RG. Gd-DTPA enhanced MR in acute cerebral infarction and in chronic ischemic changes. *Proceedings of Contrast Agents in Magnetic Resonance Imaging*, San Diego, CA January 1986, *Excerpta Medica*, pp 127-129
16. Grossman RI, Gonzales-Scarano F, Atlas SW, Galetta S, Silberberg DH. Gd-DTPA enhancement in MRI of multiple sclerosis. *Proceedings of Contrast Agents in Magnetic Resonance Imaging*, San Diego, CA January 1986, *Excerpta Medica*, pp 121-123